

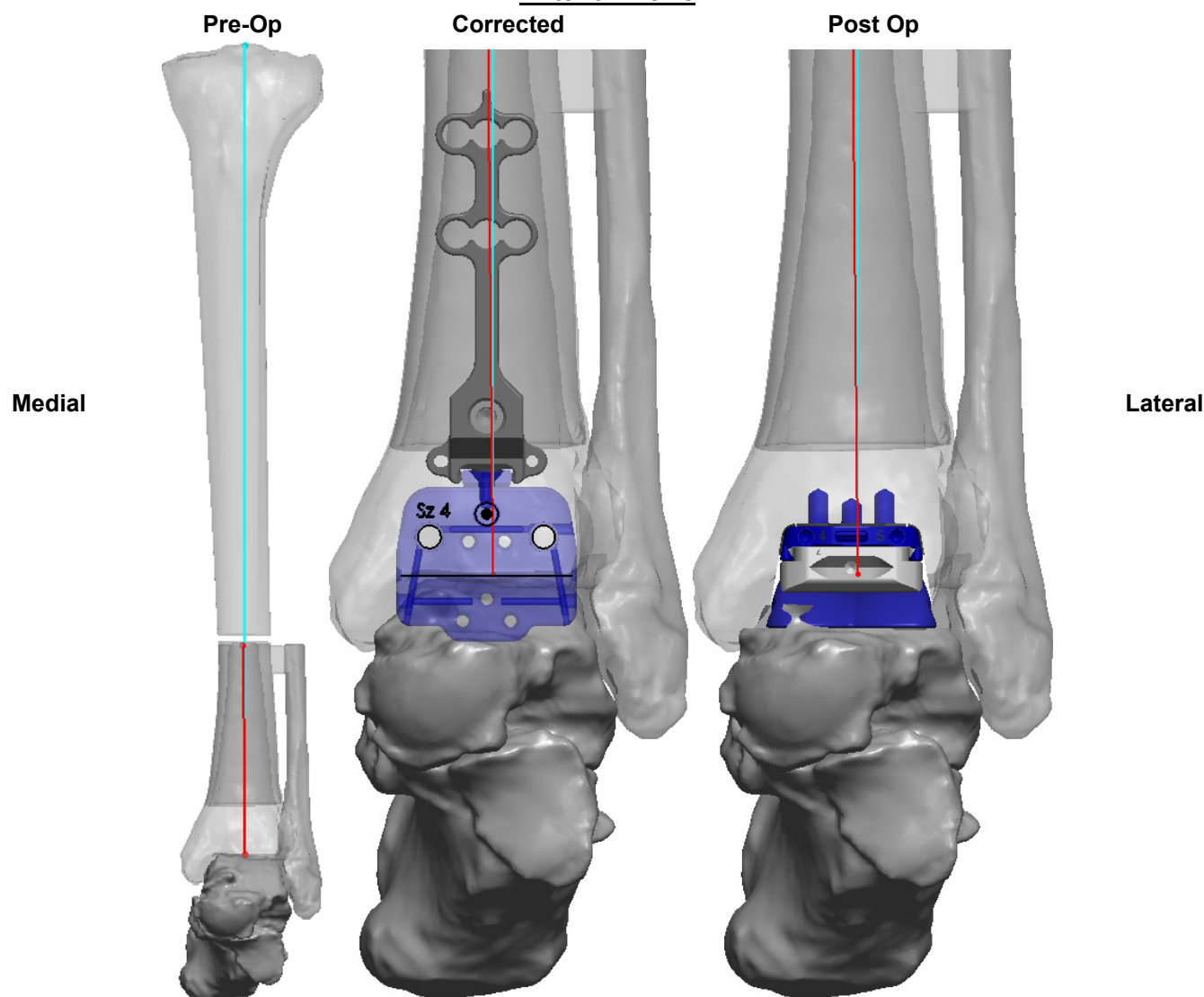
PROPHECY® INFINITY®

Preoperative Navigation Guides

Envision the Results™

CASEINFFF (CASE11155) - Surgeon: Dr. INFINITY Training
 Demo Cadaver Replacement - Left - Surgery: MM/DD/YYYY

INFINITY® Size 4 Tibia & Size 4 INFINITY Talus

Anterior Views

— Tibia Mechanical Axis
 — Tibia Anatomic axis

Axis Angles
Anatomic vs. Mechanical
 Coronal = 0.5°

Tibia Implant Alignment

- Coronal Plane: **Mechanical (long) Axis**
- Sagittal Plane: **Mechanical (long) Axis**

Medial/Lateral placement is set:

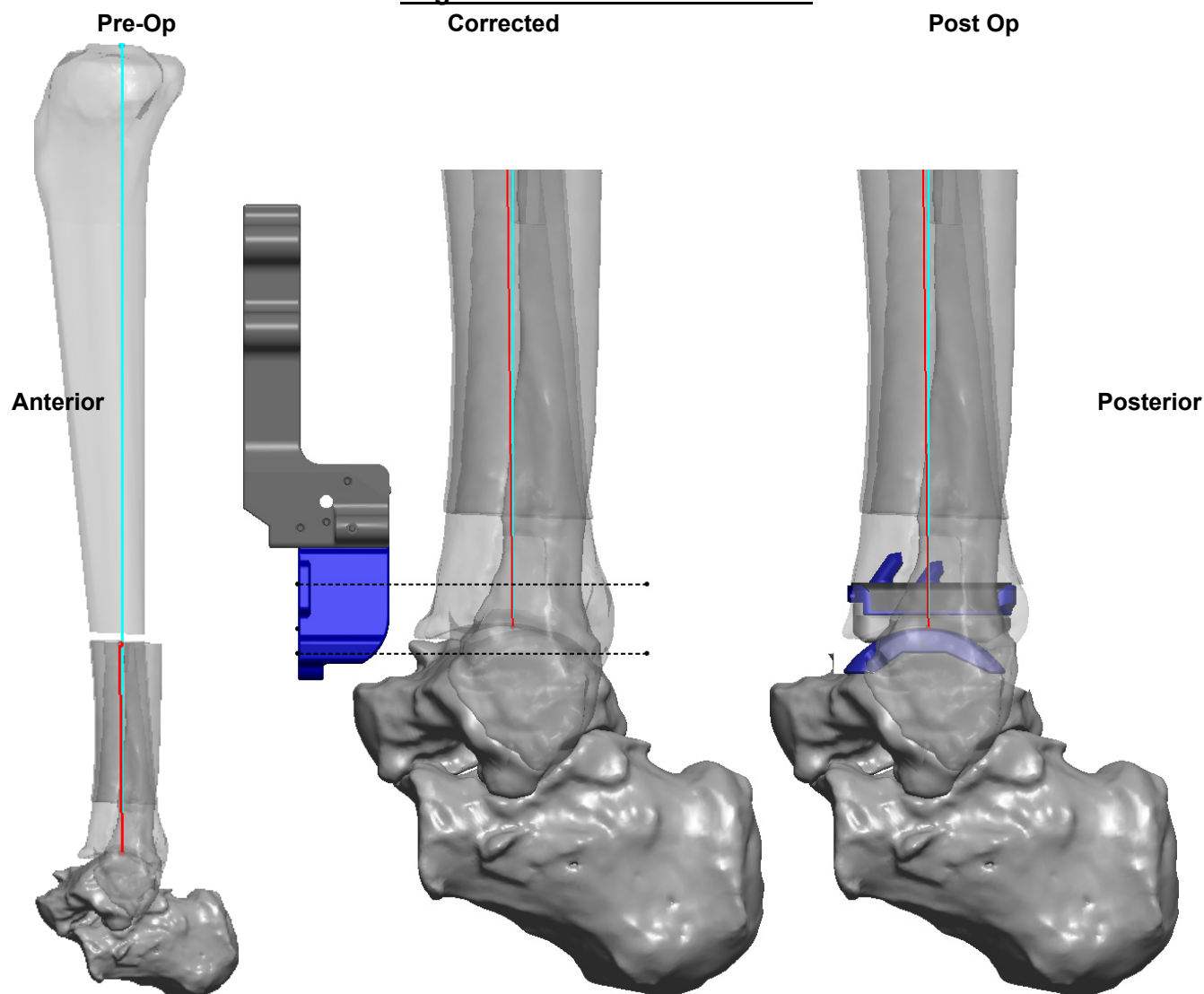
- to Match medial gutter corner
- to ensure there is bone coverage on lateral implant.
- Medial malleolus at implant corner: **13.6 mm.**

PROPHECY® INFINITY®

Preoperative Navigation Guides

Envision the Results™

INFINITY® Size 4 Tibia and Size 4 INFINITY Talus

Sagittal Views from Lateral Side

- Tibia Mechanical Axis
- Tibia Anatomic axis
- - - Resection Planes

Axis Angles
Anatomic vs. Mechanical
 Sagittal = 0.6°

Implant Information

Tibial tray: Sz 4
 (33650004)
 Tibial insert: Sz 4
 (33654406)

Talar dome: Sz 4 INFINITY
 (33630024)

PROPHECY® Part Number:
 PROPINF

Figure 1 displays two 3D surface renderings of a human mandible. The left image shows the medial view, and the right image shows the lateral view. The mandible is oriented with Anterior at the top, Posterior at the bottom, Medial on the left, and Lateral on the right. A vertical line in the medial view indicates the AP Direction. Two 8.7-degree angles are marked on the medial view. A blue shaded area in the lateral view represents the gutter bisection. A legend at the bottom indicates 'AP Direction: Gutter Bisection' with a black line.

-

3/23/2016

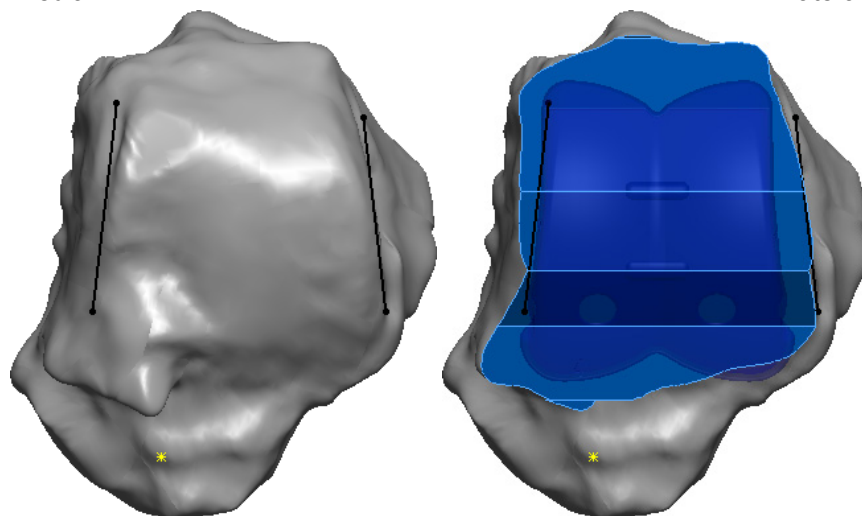
INFINITY® Size 4 Tibia and Size 4 INFINITY Talus Talus Rotation Top Views

AP Direction: Gutter bisection

Size 4 INFINITY

Medial

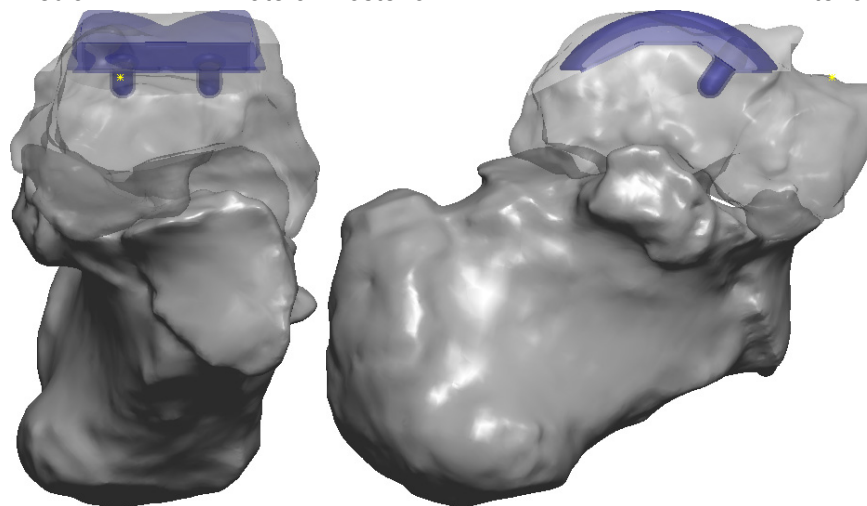
Lateral



Medial

Lateral Posterior

Anterior



Anterior view

Medial View

Notes:

- Talus resection angle in Coronal Plane: **parallel to the natural talar dome**.
- Size **4 INFINITY** talus implant is selected to maximize bone coverage while minimizing implant overhang.
- Talar Gutter angle: 13.2°. Talus anterior direction: **Gutter bisection**.
- The resection depth is set to **0 mm** more than the thickness of the talar implant.
- The distal flat of the talar implant is **1.3 mm** proximal to the yellow talar neck point shown above.

Summary

Tibial Alignment Method

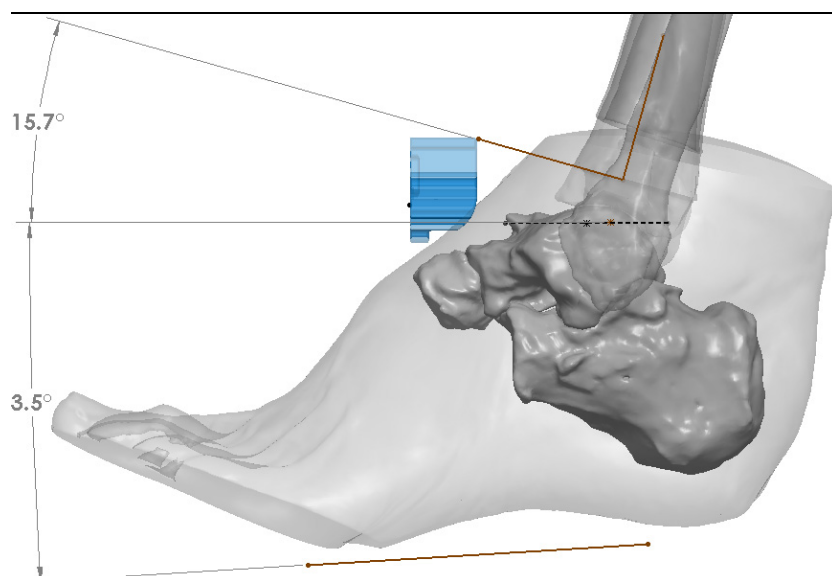
- Tibia Implant Alignment in Coronal Plane: Mechanical (long) Axis.
- Tibia Implant Alignment in Sagittal Plane: Mechanical (long) Axis.
- Anterior direction is set by the Gutter Bisection.
- Medial/lateral implant placement:
 - Match medial gutter corner.
 - The cuts on the medial malleolus and fibula are minimized.
 - Upsize for AP tibial coverage.
- Anterior/Posterior implant placement: Anterior Edge

Talar Alignment Method

- Talus implant flexion is set to: Follow the curvature of the talar dome.
- Talus implant is selected to maximize bone coverage while minimizing implant overhang.
- Anterior direction is set by Gutter bisection.
- Resection depth: 0 mm more than the thickness of the talar implant.

PROPHECY® Engineering Comments

- The talus resection is set to be parallel to the natural talar dome in the coronal plane, which results in the varus correction as shown on page 3, but the patient appears to have some residual hindfoot varus alignment in the post-op state (page 1). Please contact us if you would like to correct a different amount of coronal deformity with the talus resection.



Sagittal view of pre-op talus showing:

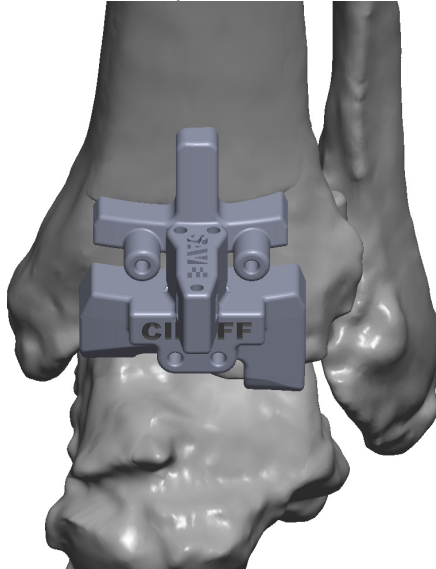
- Talus resection vs. tibia resection.
- Talus resection vs. bottom of foot line.

PROPHECY® INFINITY®
Preoperative Navigation Guides
Envision the Results™

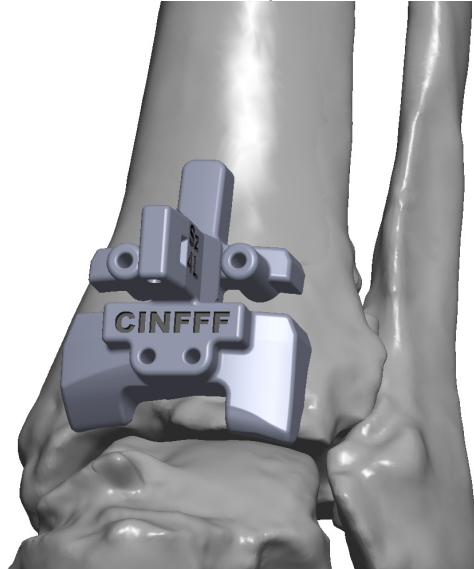


Tibial Alignment Guide

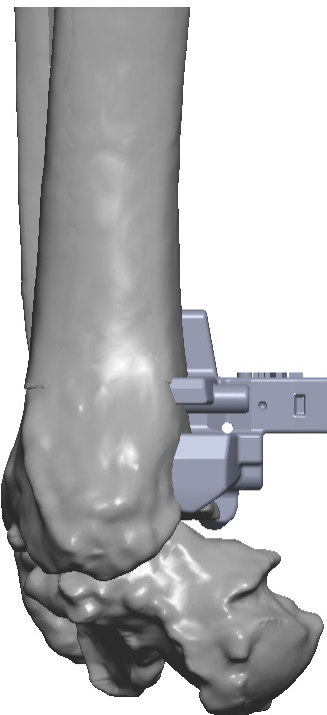
Superior view



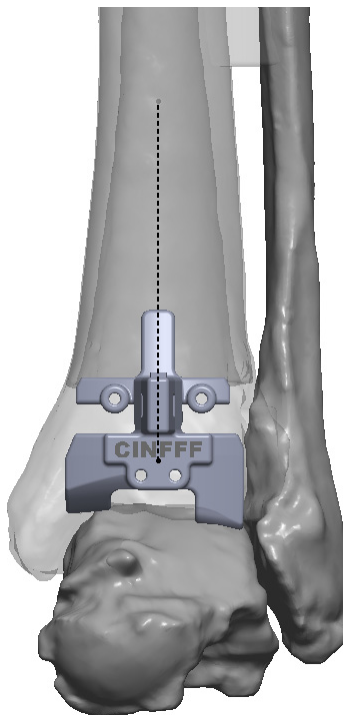
Inferior Oblique View



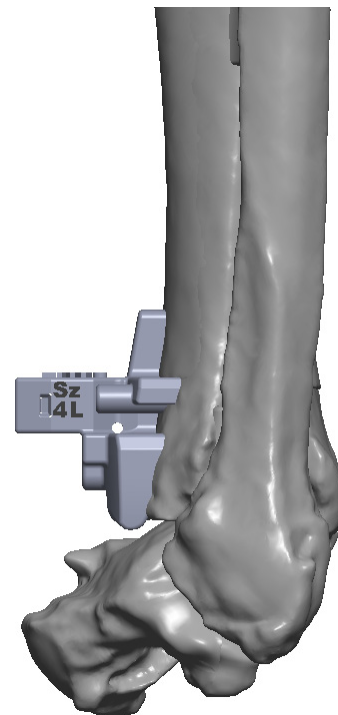
Medial view



Anterior View



Lateral View

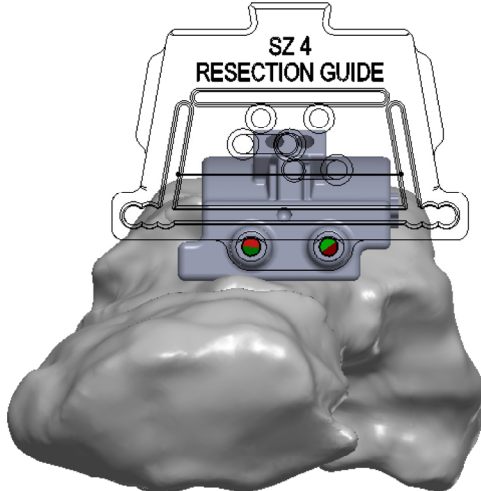


Tibia Guide Comments:


- Tibia Alignment Guide Specific Comments

Talar Alignment Guide

Anterior view, with the navicular and resection guide



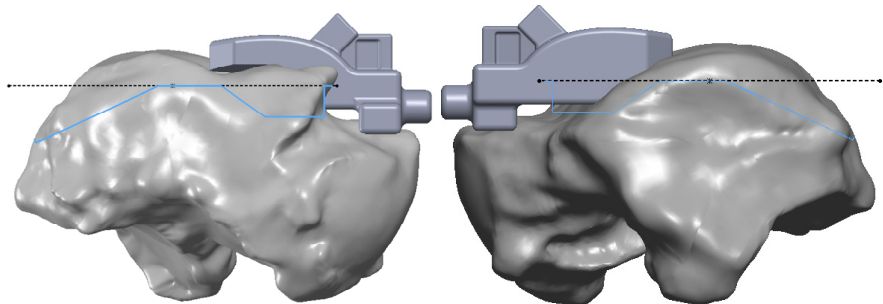

Superior Oblique View



Superior view

Medial View

Lateral View



Talus Guide Comments:

- Talar guide designed for use with: **size 4 INF-INF resection guide.**
- Talus Alignment Guide Specific Comments

PROPHECY® INFINITY®

Preoperative Navigation Guides

Envision the Results™

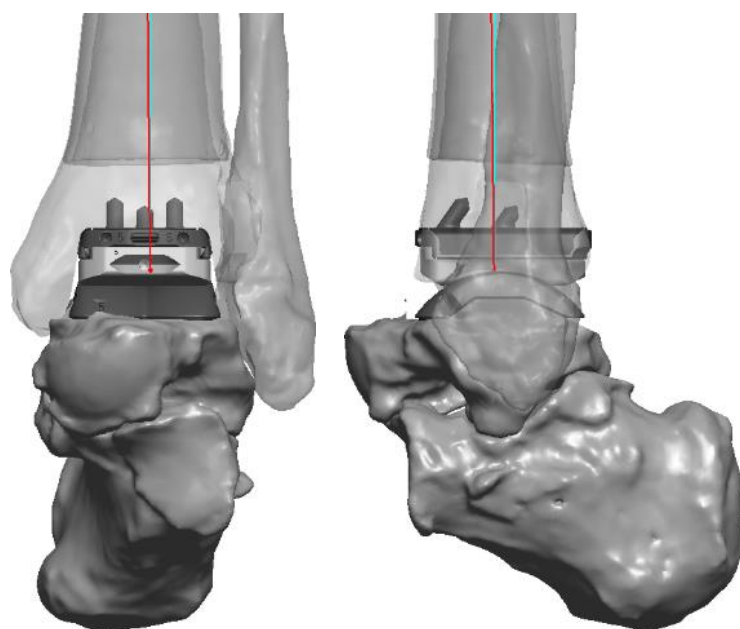
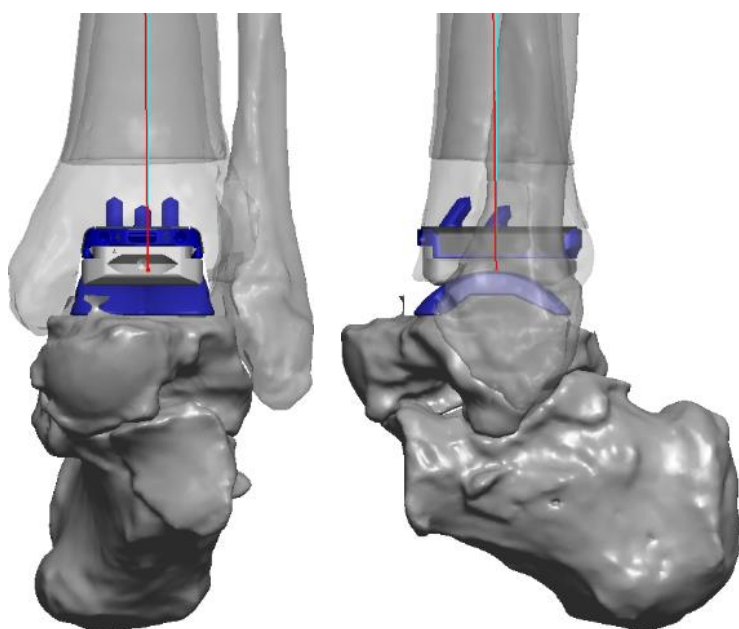


CASE11155 - APPENDIX: Alternative size implants

- This case is somewhat between sizes.
- The above report utilizes size 4 Std tibia and size 4 talus implants. An alternative size 5 Std tibia and 5 talus are shown below for comparison.
- The size 5 Std tibia tray provides better A-P coverage with some overhang. The Size 4 Std tibia implant reduces the amount of bone resected. The size 4 long tibia could be also selected, which has the same AP coverage as the size 5 Std and the same ML coverage as the size 4 long.
- The report does not need to be rejected in order to use the alternative size.

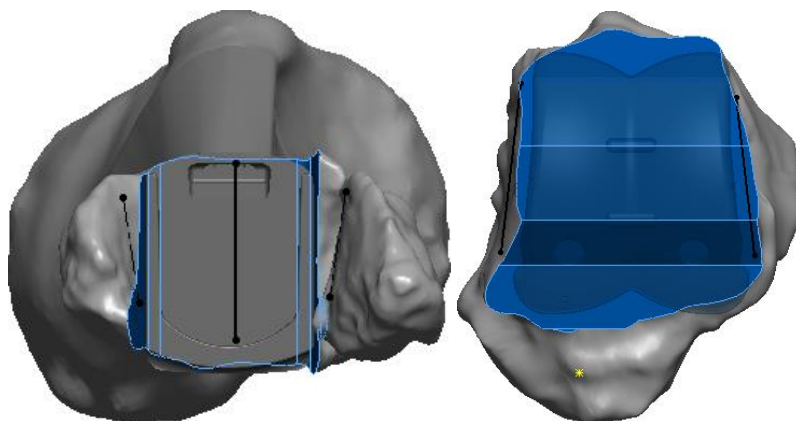
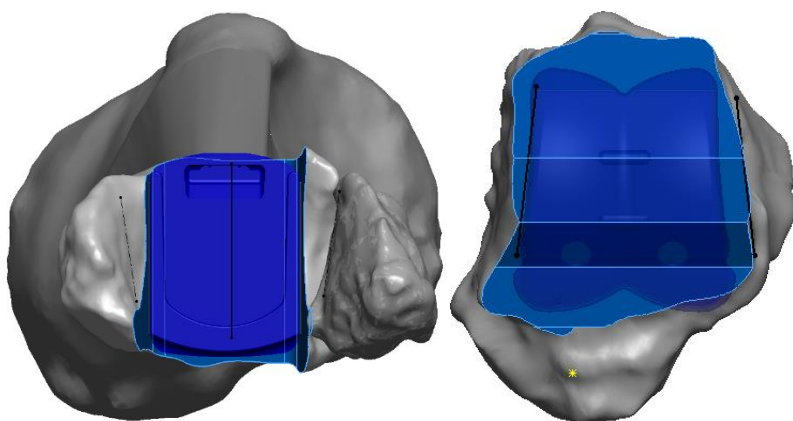
Current Size

Alternative Size



Anterior and lateral images for the current size 4 Std tibia, 4 talus implants.

Anterior and lateral images for the alternative size 5 Std tibia, 5 talus implants.



**Size 4 Std tibia.
Distal view.**

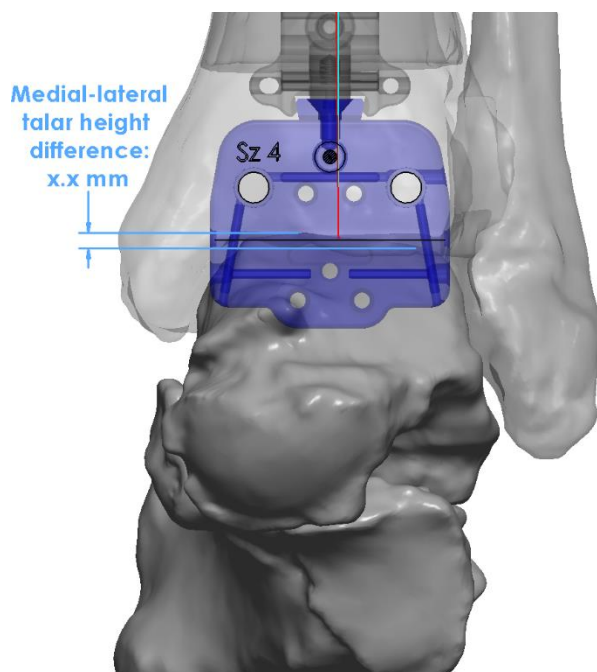
**Size 4 talus.
Proximal view.**

**Size 5 Std tibia.
Distal view.**

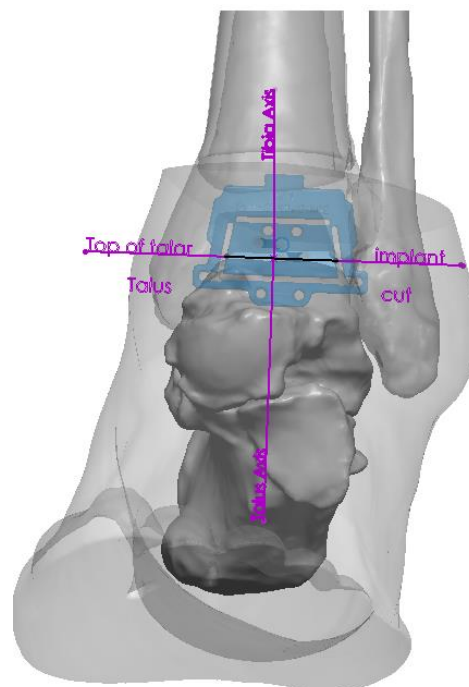
**Size 5 talus.
Proximal view.**

PROPHECY® INFINITY®

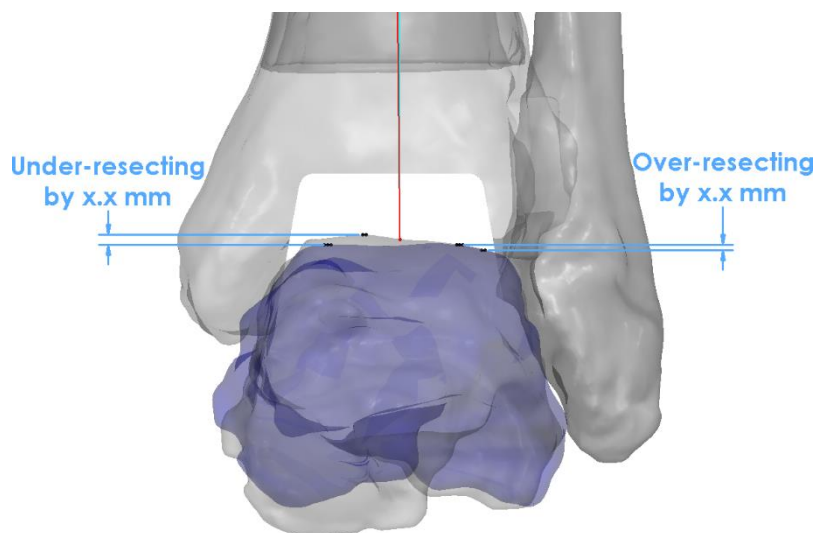
Preoperative Navigation Guides

Envision the Results™**CASE11155 - APPENDIX: Talus Resection Angle and Tibia Resection Height**

Pre-op medial-lateral talar height difference:
x.x mm



Talus resection guide relative to the talar bone and the planned tibia alignment axis. The resections will result in a correction of 2.2° from varus.



The swing of the talus & overall resection height (relative to standard implant height). The "corrected" talus is highlighted.

The tibia resection height has been set as shown by the "under-resecting" value to restore some height of the joint. This distal translation of the talus means resecting less bone than the full height of the implant on one side to reduce the likelihood of requiring the thickest polyethylene. Given the current tibia resection height and the thinnest polyethylene, it is expected that the high side of the talus will be forced distally by the "under-resecting" measurement, and the opposite side may have residual laxity in the amount of the "over-resecting" value. Ligament balancing may be necessary to achieve correction.

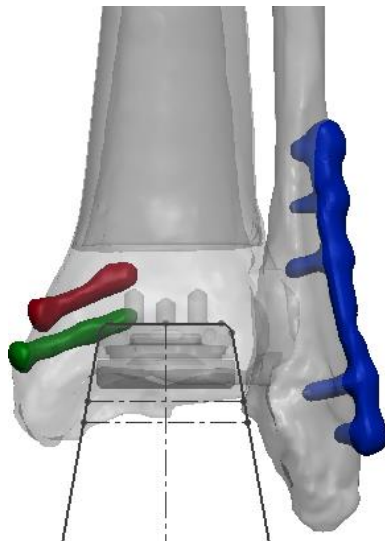
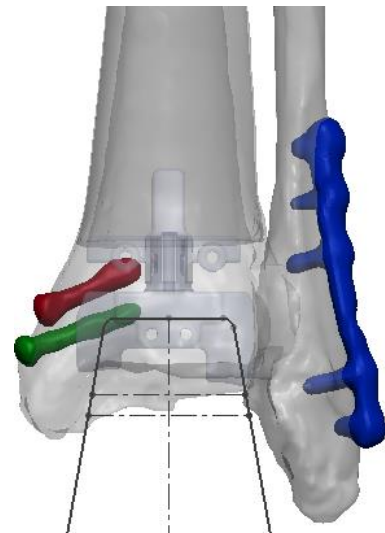
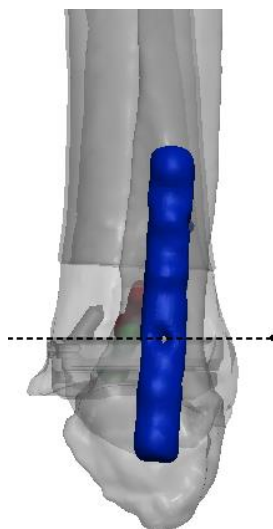
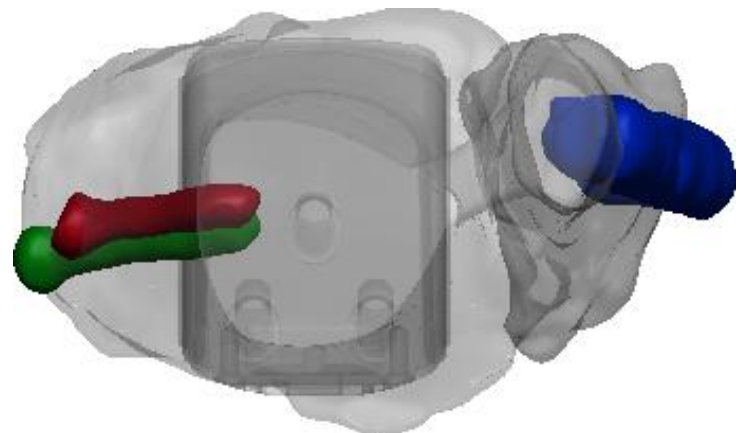
PROPHECY® INFINITY®

Preoperative Navigation Guides

Envision the Results™**CASE11155 - APPENDIX: Hardware proximal to the joint line**

Hardware exists as shown below. The relationship between the hardware and the features of the planned TAR procedure are specified as follows. If the hardware identified as interfering is not planned to be removed prior to completing the PROPHECY® procedure, please contact us to discuss. Hardware close to interfering may also need to be removed.

- The tibia resections and implant interfere with the hardware colored green.
- The k-wire used for the instrumentation interferes with the hardware colored red.
- The hardware shown in blue color does not interfere directly with any PROPHECY®-related aspect of this case.

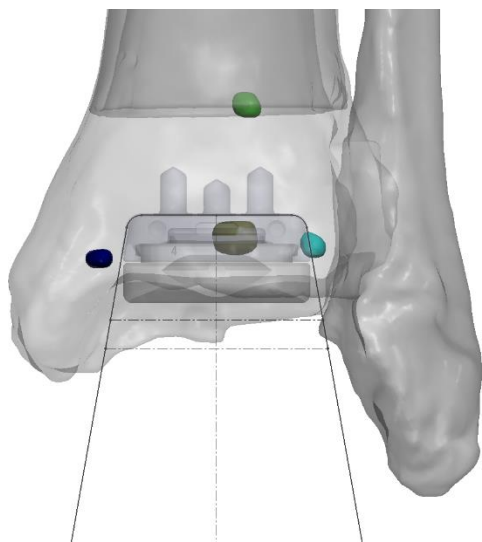
**Anterior view****Anterior view – alignment guide****Sagittal view****Proximal view**

PROPHECY® INFINITY®

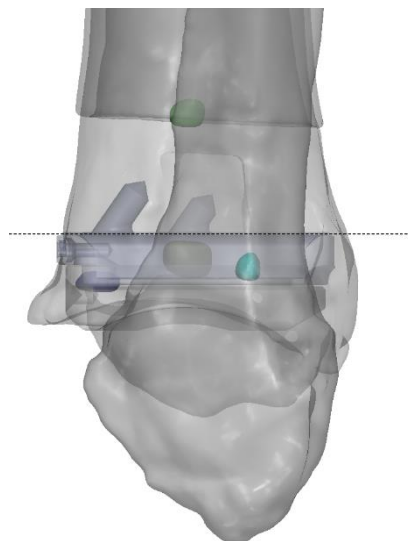
Preoperative Navigation Guides

Envision the Results™**CASE11155 - Bone Void Appendix**

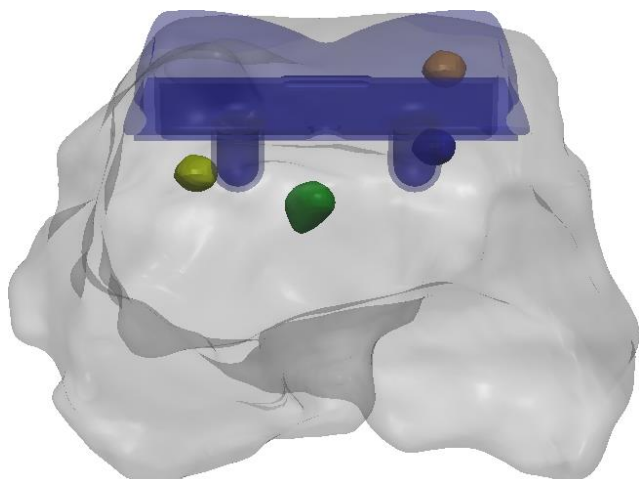
Any bone voids are shown below relative to the implants and resection planes. Please refer to the patient's CT scan for more details.



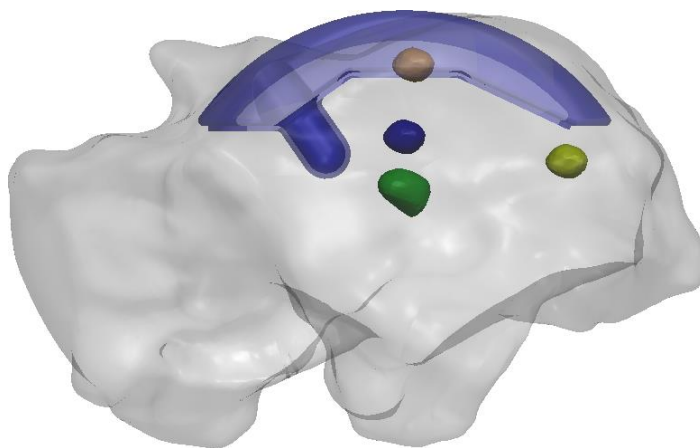
Anterior view of tibia and fibula with implant.



Lateral view of tibia and fibula with implant.



Anterior view of talus with implant.



Sagittal view of talus with implant.

PROPHECY® INFINITY®

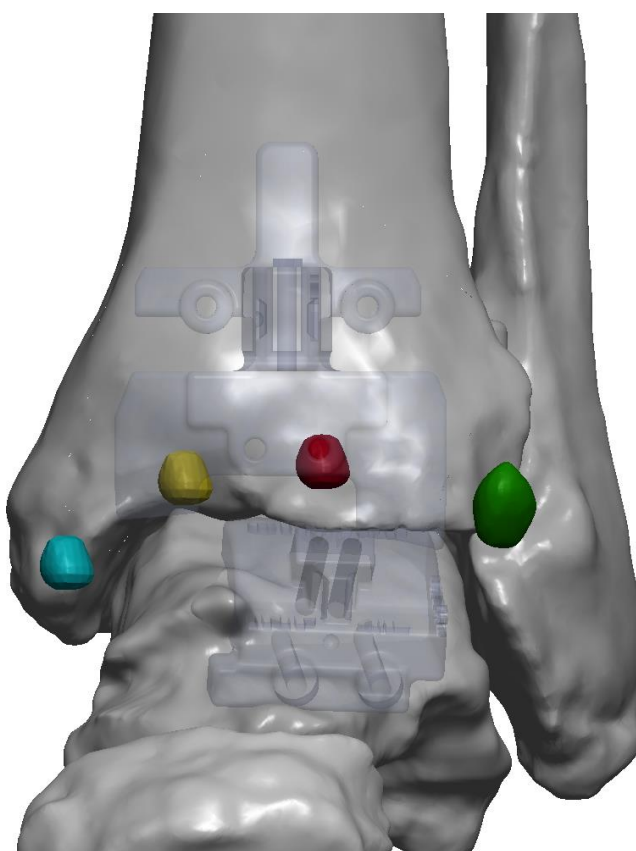
Preoperative Navigation Guides

Envision the Results™



CASE11155 - Osteophyte Appendix

- Any loose body osteophytes shown below that interfere with the alignment guides will need to be removed prior to placing the guides.



Alignment guides at tibia-talus joint line
relative to any loose osteophytes. Anterior
view